

## Analyzing the histological alterations in quail tissues following the administration of different triamcinolone doses

<sup>1</sup>Munazza Ghaffoor, <sup>1\*</sup>Saima Noreen, <sup>2</sup>Sidra Muhyuddin, <sup>3</sup>Muniba Mumtaz, <sup>3</sup>Shabab Zahra, <sup>4</sup>Asma Malik, <sup>5</sup>Tabinda Afzal, <sup>6</sup>Jawaria Farooq, <sup>7</sup>Samra Idrees, <sup>8</sup>Farzana Yasmeen, <sup>9</sup>Shane Fatima Malik

### Corresponding Author:

Saima Noreen ... Lecturer of Zoology in Muhammad Nawaz Sharif University of Agriculture Multan

### **Abstract:**

Triamcinolone is a synthetic glucocorticoid widely used. Glucocorticoids have a wide range of impacts on physiological processes. The present research was conducted to explore the deleterious effects of triamcinolone on vital organs like the liver, kidneys, muscles, and brain in common quail. Total 120 birds were purchased from the market. 60 birds were used in winter and 60 in spring trial. These divided into three groups one kept as control, second group was given (low concentration 0.02ml/mg) and third group received are (high concentration 0.04ml/mg) of Triamcinolone. Clinical manifestations include such as vision impairment, formation of skin blisters, irritation, congested nasal passages, scaling of the skin, redness at the injection site and feelings of nausea. Histopathological examination of different tissues the impact of steroids on the serum biochemistry profile revealed significant harm to essential organs, with elevated levels of cholesterol and uric acid in both the liver and kidneys. The liver tissue samples showed hepatocytes arranged in chains, pyknotic and necrotic changes in a few regions, moderate cytoplasm swelling and no nuclei. Extensive vacuolation of the showed kidney tissue sample and focal necrosis tubular inflammation can be observed. Although, there was no change we observed in the control group. Muscle tissue samples showed cell swelling. Likewise, in brain tissue samples, we observed blurry swelling and inflammation. However there is no change in the control group was observed.

**Key Words:** Triamcinolone, Quail, Histokinetics, Myofibers, Vacuolation, Glucocorticoids.

### **1. Introduction**

Common quail is ground, tropical and temperate birds (Altine et al., 2016). Grasslands are the common quail's overall habitat. Dense, high vegetation is preferred, while edges of forests and hedgerows are prevented (Németh, 2019). Also used as nesting cover are cultivated areas of winter

wheat, clover and tiny green plants (Kauffman et al., 2021). Quail possess advantages such as swift growth, compact size, improved lying ability, a brief life cycle, delectable meat flavor, and quicker hatching duration compared to other avian species (Forshaw, 2023).

### **1.1 Triamcinolone:**

Triamcinolone is a synthetic glucocorticoid widely used. Glucocorticoids have a wide range of impacts on physiological processes (Hardy et al., 2020) Weight loss and weakness of triamcinolone were recorded, and Dubois also stated that triamcinolone was not the preferred medicine for Systemic lupus erythematosus (Wallace, 2018). Also stated were other side effects such as headache, dizziness, weight loss and lack of appetite (Gündüz, 2023). This study aimed to assess the detrimental impacts of Triamcinolone on the histopathological aspects of quail birds.

## **2. Materials and Methods**

### **2.1 Experimental Birds:**

Common quail (*Coturnix Coturnix*) is a tiny bird of family Phasianidae. It is a wandering bird with long wingspan. This is a terrestrial species, feeding on seeds and bugs at the floor. This quail breeds on airable farmland, laying 6-12 eggs in a floor check. The eggs take from 16-18 days to hatch.

Twenty four female wholesome common quail (*Coturnix Coturnix*) had been purchased from essential nearby marketplace of quails. The birds' age at the beginning of the experiment was 25-30 days. Birds frame weighing was eighty to a hundred gram at the buying time. Such species of birds have been stored in Bio park of Bahauddin Zakariya University, Multan.

### **2.2 Bird conditions and experimental development:**

Quails are housed in fully illuminated, wiped clean and ventilated space in metal cord cages.

Earlier than the beginning of the test, they were very well observed. The feed became remedy loose homemade vitamins (maize, beans). Fresh and smooth water was supplied three instances in line with day. Until five days before the start of treatment, all birds are conditioned and converted to animal residence status (Huss et al., 2008).

### **2.3 Drug design:**

In the course of experimental duration only one drug became used. Injection of Triamcinolone turned into introduce I/M daily. The quantity of the drug formula needed is calculated by the frame

weight of the bird. All quails had been categorized into two corporations control and treated (Yáñez et al., 2011).

## **2.4 Dose fixation:**

Handiest one drug was used on this experiment. 5 sub organizations, every of five birds, had been injected given drug for 10 days and different 5 subgroups had been injected drug 20 days once an afternoon weight structured healing dose (low dose ). Different 5 subgroups have been injected the identical drug for 10 days and relaxation of the 5 subgroups for 20 days as soon as afternoon double the dose (high dose) of therapy.

After five days of programming language time, birds were weighted and rectal temperature was also frequently reported with digital thermometer. Body state is frequently referred to by birds. Ten days after 10 days, birds are killed and 20 days after 20 days.

Experimentation was carried out two times: winter and spring season trial.

Injections have been given at weight established: Low and High dose.

**Low dose 0.02ml/mg , High dose 0.04ml/mg**

## **3. Protocol for Histopathology**

### **3.1 Microtomy Procedure:**

The initial step involves slicing tissues from vital organs into thin sections of 6 micrometers, followed by immersion in a saline solution at room temperature for a 5-hour fixation period.

### **3.2 Dehydration Process:**

To eliminate excess liquid from tissues, a desiccation process is employed. This involves a sequential treatment with various concentrations of alcohol and other desiccating agents, effectively removing water content from tissues securely held in an aqueous environment.

### **3.3 Tissue Clearing:**

Subsequently, the tissues undergo a transparency-enhancing phase by immersion in clove oil until they achieve translucency. Following this, the tissues undergo two rounds of benzoyl treatment for 10-12 minutes each, and finally, they are transferred to a 1:1 mixture of benzoyl and paraffin wax for 20-25 minutes at 60°C repeated twice.

### **3.4 Embedding:**

Post-clearing, the tissues are prepared for block formation, mounted on wooden blocks, and cut into segments of 6 micrometers width using a Richert microtome.

### 3.5 Deparaffinization:

The cut pieces are affixed to pre-washed albumenized glass slides, heated at 60°C on a Fisher slide warmer, and subsequently moved to an oven at the same temperature for complete deparaffinization.

### 3.6 Staining:

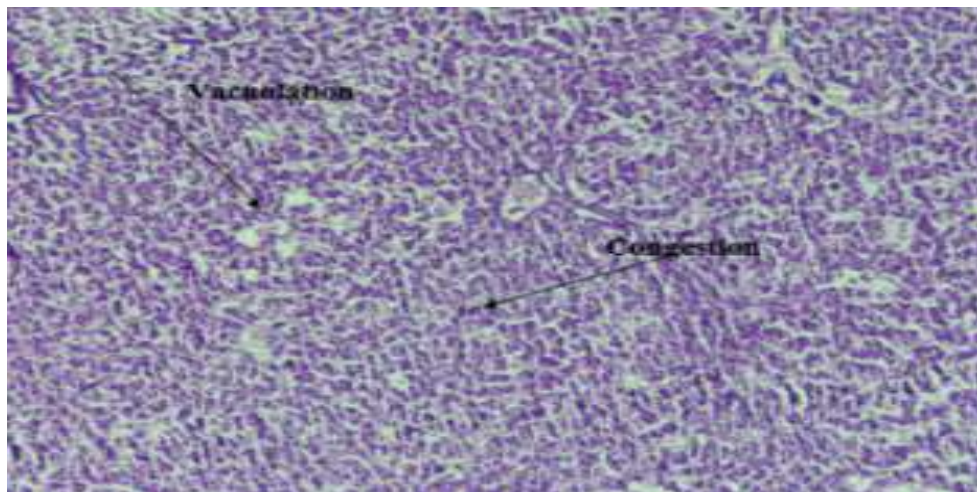
After removal of any remaining wax in xylene for half an hour, the slides undergo dehydration using descending alcohol grades. Following a 5-minute wash with tap water, the slides are stained with hematoxylin for the removal of residual wax. Dehydration is repeated with ascending alcohol grades, and finally, eosin is applied for 1/2-2 minutes. Completed slides are mounted in Canada balsam, and microphotographs are captured using a camera-equipped microscope.

## 4. Results

### Comparative analysis of histological assessment of liver tissue samples in control and treated bird groups

#### 4.1 Winter Trial:

**Control:** we did not observe any specific changes during the course of trials in control groups, while changes were detected in treated birds (Figure 1).

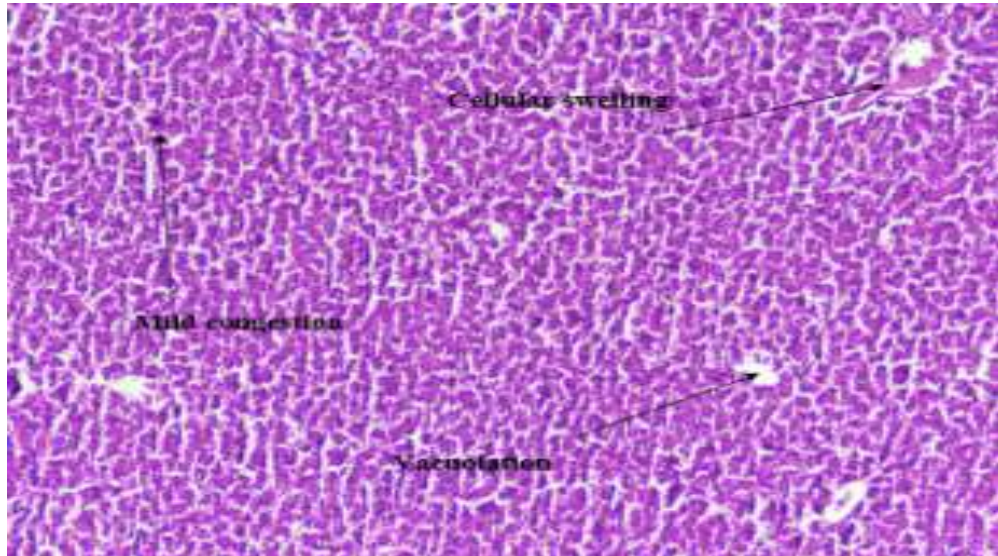


**Figure 1.** A photomicrograph of liver showing excessive vacuolation, cellular swelling, necrosis, congestion and prominent inflammatory response

## 4.2 Spring Trial:

### Control:

No changes were detected in control birds throughout the course of trial. Changes observed in birds treated by triamcinolone (Figure 2).

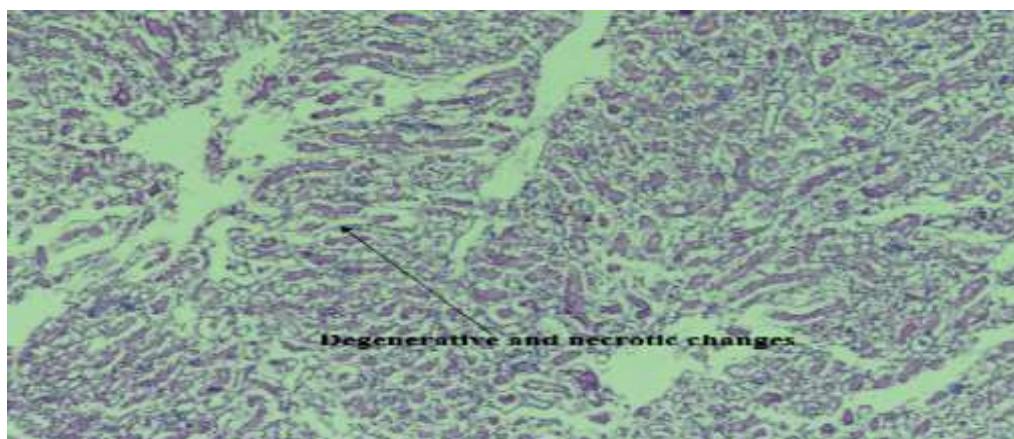


**Figure 2. A photomicrograph of liver showing inflammatory cells, vacuolation, mild congestion and cellular swelling**

## Comparative analysis of histological assessment of kidney tissue samples in control and treated bird groups

### 4.3 Winter Trial:

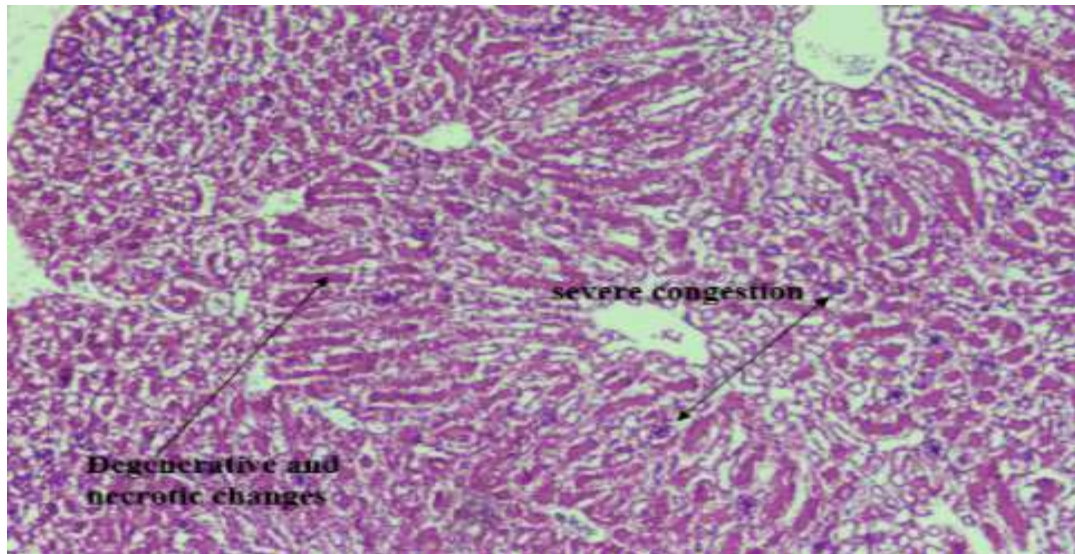
**Control:** we did not observe any specific changes during the course of trails in control groups. Vacuolation and pink material detected in treated birds (Figure 3)



**Figure 3. A Photomicrograph of kidney showing degenerative and necrotic changes**

#### 4.4 Spring Trial:

**Control:** Throughout the experimental trials, no distinctive shifts were noted in the control groups, Variations in the treated birds were observed (Figure 4)

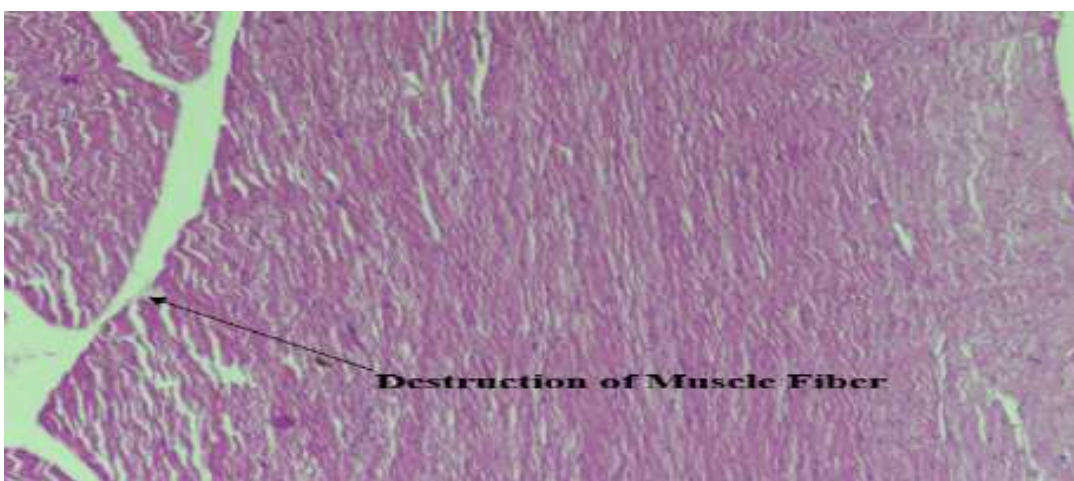

**Figure 4. A Photomicrograph of kidney showing degenerative and necrotic changes in the tubular epithelium along with severe congestion in the renal**

Comparative analysis of histological assessment of muscle tissue Samples in control and treated bird groups.

#### 4.5 Winter Trial:

**Control:** we did not observe any specific changes during the course of trails in control groups. Swelling of muscle fiber in treated birds were observed (Figure 5)

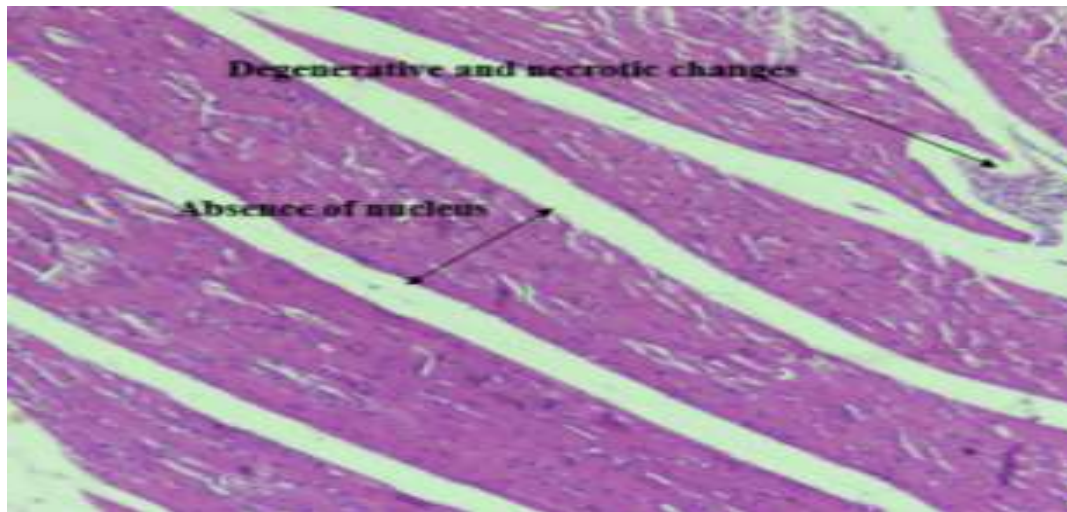


**Figure 5. A Photomicrograph of muscle showing degenerative and necrotic changes in the myofibers**

#### **4.6 Spring Trial**

##### **Control:**

Birds kept in control conditions don not show any changes during trial. While changes detected in treated birds (Figure 6).



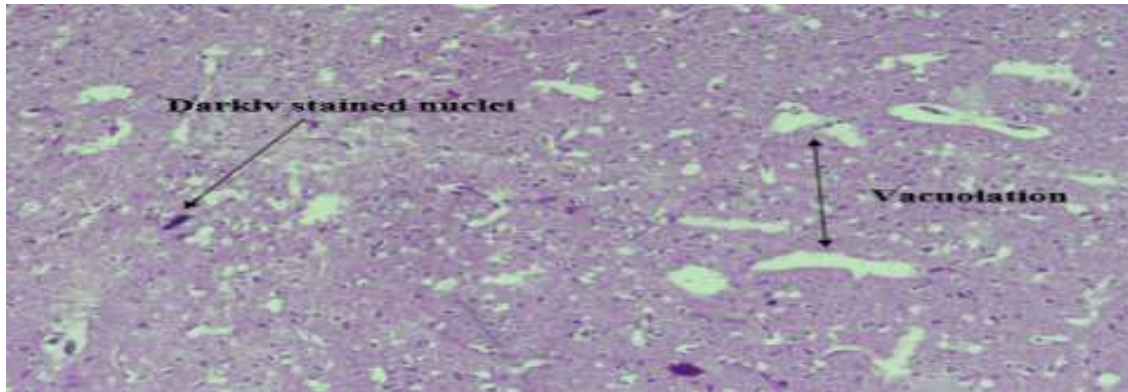
**Figure 6. A Photomicrograph of myofibers showing degenerative, necrotic changes and absence of nucleus.**

**Comparative analysis of histological assessment of brain tissue samples in control and treated bird groups.**

#### **4.7 Winter Trial:**

##### **Control**

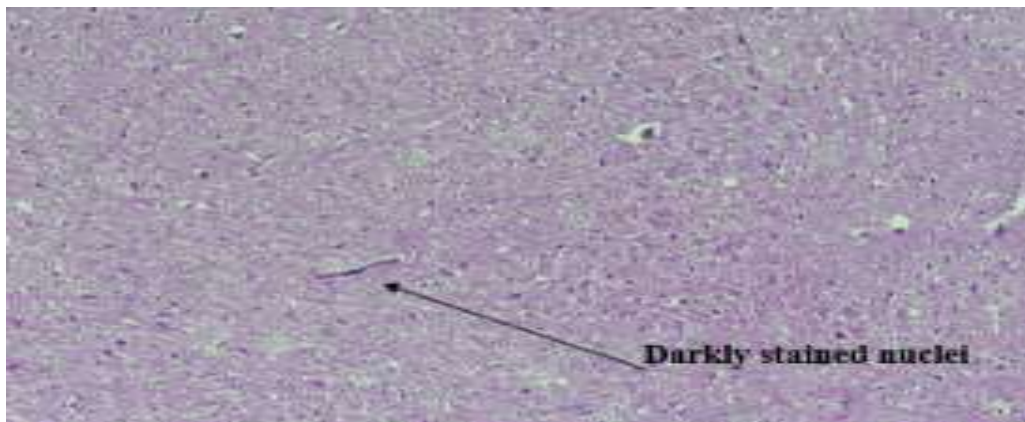
No specific changes were found in control groups during the course of the trails. Vacuolation appeared in treated birds (Figure 7).



**Figure 7. A Photomicrograph of cerebral cortex showing vacuolation in along with darkly stained nuclei.**

#### **4.8 Spring Trial**

**Control:** There were no changes detected in the standard birds while changes observed in treated quails (Figure 8)



**Figure 8. A micrograph image of the cerebral cortex reveals the presence of vacuolation within the cell cytoplasm, accompanied by nuclei that exhibit a dark stained nuclei.**

#### **4.9 Comparison of body weight and body temperature:**

Body weight of birds decrease in this study. In one-way ANOVA body weight of birds showed significant result when we compared control bird with treated birds( $p=0.000^*$ ) this is shown in (Table.2). There was significant difference in body temperature in 10 and 20 days ( $p=0.041^*$ ,  $0.019^*$ ) respectively (Table 1).



**Table 1. Comparison of body temperature in common quail in 20 days long winter trial experiment, data is showed as Mean St. deviation and St. Error. P value shows the analytical observations of independent sample t test.**

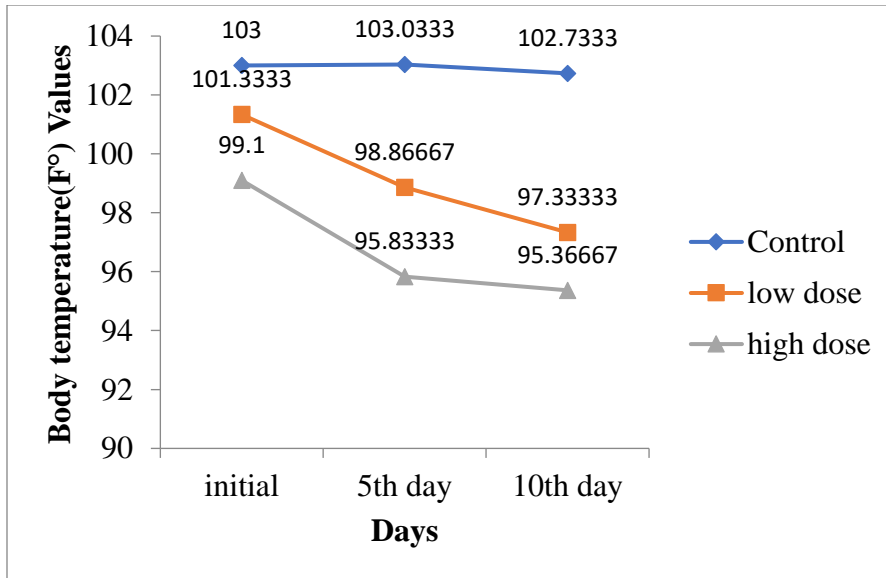
Variables	Days	Mean	St. Deviation	St. Error	Significance
Body temperature	10	101.9370	4.42164	0.85094	0.041*
	20	98.3133	8.34518	1.24403	0.019*

**P > 0.05 Non significant, P ≤ 0.05 Significant (\*), P ≤ 0.01 Strong Significant (\*\*)**

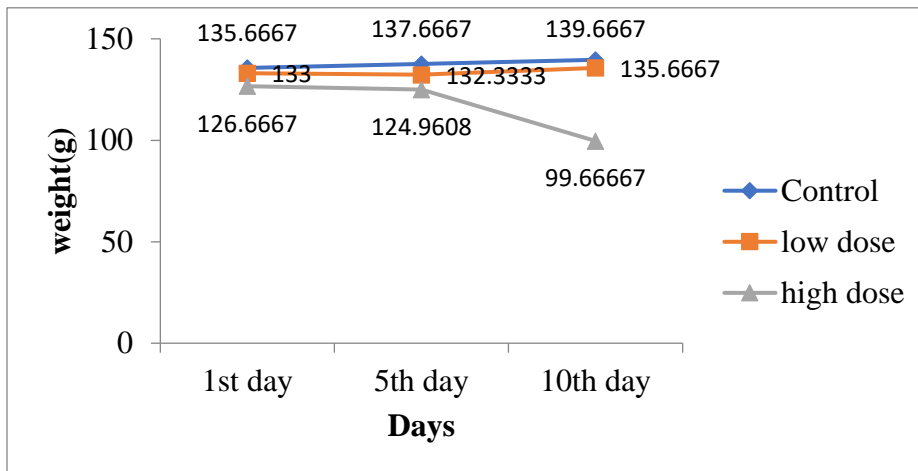
**Table 2. Body weight relation in common quail in 20 days long winter trial experiment, P value shows the statistical observations of one-way ANOVA**

Group	Dose	Significance
Control	Low	.000*
	High	.000*
Low	Control	.000*
	High	.000*
High	Control	.000*
	Low	.000*

**P > 0.05 Non significant, P ≤ 0.05 Significant (\*), P ≤ 0.01 Strong Significant (\*\*)**



**Figure 9. The median correlation (n=3) Control body temperature and the Triamcinolone handled birds in 10 days winter trial.**



**Figure 10. The median correlation (n=3) Control body weight and the Triamcinolone handled birds in 10 days winter trial**

### 5. Discussion

In this study, birds subjected to triamcinolone treatment exhibited distinctive indicators such as swelling of spleen, vision impairment and formation of skin blisters, irritation, congested nasal passages, scaling of the skin, redness at the injection site and feelings of nausea (Meuninck, 2014). Kidney histopathology revealed that this analysis increased the Epithelial cell loss, increased cell penetration, increased blood vessels congested, increased homogeneous pink tissue, and increased

glomerular volume (Villarreal et al., 2021). All these changes were found in this analysis in the kidneys of birds treated with triamcinolone. Extensive vacuolation of kidney tissue sample and focal necrosis tubular inflammation can be observed (Treviño, 2021). Muscle cell shows degenerative and necrotic changes in the myofibers (Kenanidis et al., 2020) The liver tissue samples showed necrotic changes in few regions, moderate cytoplasm swelling and no nuclei (Abd El-Rahman et al., 2020). In brain tissues blurry swelling and inflammation was observed (Siqueira et al., 2015). In general, the influence of steroids on the serum biochemistry profile indicated serious harm to vital organs elevated liver and levels of cholesterol and uric acid. The medical symptoms as noted as anxiety, inflammation of joints, swelling on spleen and dizziness.

## 6. Conclusion

Triamcinolone treatment has led to histopathological variations in the liver, kidney, brain, and bird muscles. These changes indicate potential impacts on the tissue structures of these organs and muscles. Further analysis is needed to understand the specific nature and implications of these variations.

## Acknowledgement

Department of Zoology, Faculty of Veterinary and Animal Sciences, Muhammad Nawaz Sharif University of Agriculture Multan, Pakistan and special thanks to Madam Saima Noreen for giving us this opportunity.

## Conflict of Interest

The authors declare no conflict of interest.

## References:

1. Altine, S., Sabo, M. N., Muhammad, N., Abubakar, A., & Saulawa, L. A. (2016). Basic nutrient requirements of the domestic quails under tropical conditions: A review. *World scientific news*, 2(49): 223-235.
2. Németh, T. M., Kelemen, P., Csiszár, Á., Kovács, G., Faragó, S., & Winkler, D. (2019). Habitat selection of the Common Quail in an intensively managed agricultural environment. *Ornis Hungarica*, 27(1): 99-109.
3. Kauffman, K. L., Elmore, R. D., Davis, C. A., Fuhlendorf, S. D., Goodman, L. E., Hagen, C. A., & Tanner, E. P. (2021). Role of the thermal environment in scaled quail (*Callipepla squamata*) nest site selection and survival. *Journal of Thermal Biology*, 95, 102791.

4. Forshaw, J. M. (2023). Quail, Buttonquail and Plains-wanderer in Australia and New Zealand.
5. Hardy, R. S., Raza, K., & Cooper, M. S. (2020). Therapeutic glucocorticoids: mechanisms of actions in rheumatic diseases. *Nature Reviews Rheumatology*, 16(3): 133-144.
6. Wallace, D. J. (2018). Systemic and Biologic Agents for Lupus Erythematosus. *Biologic and Systemic Agents in Dermatology*, 377-390.
7. Gündüz, B. Ü. L. E. N. T. (2023). Reproductive Development of Japanese Quail (*Coturnix coturnix japonica*) in Males and Females Subjected to Leptin Injections. *Acta Veterinaria Eurasia*, 49(3): 23-78.
8. Huss, D., Poynter, G., & Lansford, R. (2008). Japanese quail (*Coturnix japonica*) as a laboratory animal model. *Lab animal*, 37(11): 513-519.
9. Yáñez, J. A., Remsberg, C. M., Sayre, C. L., Forrest, M. L., & Davies, N. M. (2011). Flip-flop pharmacokinetics—delivering a reversal of disposition: challenges and opportunities during drug development. *Therapeutic delivery*, 2(5): 643-672.
10. Meuninck, J. (2014). *Basic illustrated Poisonous and Psychoactive plants*. Rowman & Littlefield.
11. Treviño-Villarreal, J. H., Reynolds, J. S., Langston, P. K., Thompson, A., Mitchell, J. R., & Franco Jr, R. A. (2021). Down-Regulation of a Profibrotic Transforming Growth Factor- $\beta$ 1/Cellular Communication Network Factor 2/Matrix Metalloprotease 9 Axis by Triamcinolone Improves Idiopathic Subglottic Stenosis. *The American Journal of Pathology*, 191(8): 1412-1430.
12. Treviño-Villarreal, J. H., Reynolds, J. S., Langston, P. K., Thompson, A., Mitchell, J. R., & Franco Jr, R. A. (2021). Down-Regulation of a Profibrotic Transforming Growth Factor- $\beta$ 1/Cellular Communication Network Factor 2/Matrix Metalloprotease 9 Axis by Triamcinolone Improves Idiopathic Subglottic Stenosis. *The American Journal of Pathology*, 191(8): 1412-1430.
13. Kenanidis, E., Kyriakopoulos, G., Kaila, R., & Christofilopoulos, P. (2020). Lesions of the abductors in the hip. *EFORT Open Reviews*, 5(8): 464-476.
14. Abd El-Rahman, G. I., Behairy, A., Elseddawy, N. M., Batiha, G. E. S., Hozzein, W. N., Khodeer, D. M., & M. Abd-Elhakim, Y. (2020). *Saussurea lappa* ethanolic extract

- attenuates triamcinolone acetonide-induced pulmonary and splenic tissue damage in rats via modulation of oxidative stress, inflammation, and apoptosis. *Antioxidants*, 9(5): 396.
15. Siqueira, R. C., Dos Santos, W. F., Scott, I. U., Messias, A., Rosa, M. N., Cunha, G. M. F., ... & Jorge, R. (2015). Neuroprotective effects of intravitreal triamcinolone acetonide and dexamethasone implant in rabbit retinas after pars plana vitrectomy and silicone oil injection. *Retina*, 35(2): 364-370.